

# Efficacy of clarithromycin as a protective agent in the methotrexate-induced pulmonary fibrosis model



Serdar Kalemci<sup>1</sup>, Orhan Akpınar<sup>2</sup>, Yelda Dere<sup>3</sup>, Aydın Sarihan<sup>4</sup>, Arife Zeybek<sup>5</sup>, Özgür Tanrıverdi<sup>6</sup>

<sup>1</sup>Department of Chest Disease, Medical Faculty, Mugla Sıtkı Kocman University, Mugla, Turkey

<sup>2</sup>Department of Medical Microbiology, Institute of Health Sciences, Suleyman Demirel University, Isparta, Turkey

<sup>3</sup>Department of Pathology, Medical Faculty, Mugla Sıtkı Kocman University, Mugla, Turkey

<sup>4</sup>Department of Emergency Medicine, Manisa State Hospital, Manisa, Turkey

<sup>5</sup>Department of Chest Surgery, School of Medicine, Mugla Sıtkı Kocman University, Muğla, Turkey

<sup>6</sup>Department of Medical Oncology, School of Medicine, Mugla Sıtkı Kocman University, Muğla, Turkey

Kardiokirurgia i Torakochirurgia Polska 2018; 15 (4): 209-212

## Abstract

**Introduction:** Methotrexate is a cytotoxic agent used in leukemia, and several other cancer types and at lower doses in auto-inflammatory diseases such as rheumatoid arthritis, ankylosing spondylitis and psoriasis. Macrolide antibiotics are effective against gram-positive and Gram-negative bacteria. They have anti-inflammatory activities as well. Clarithromycin is a macrolide with anti-inflammatory activity through blockage of the p38 MAPK signal cascade, which is involved in methotrexate-induced pulmonary toxicity.

**Aim:** In this study, the efficacy of clarithromycin in protecting against pulmonary fibrosis was investigated in the rat model for methotrexate-induced pulmonary fibrosis.

**Material and methods:** A total of 30 female rats were divided into three groups. Group I was administered intraperitoneal and intragastric saline; group II was administered oral 3 mg/kg methotrexate; and group III was administered oral 3 mg/kg methotrexate + intraperitoneal 200 mg/kg clarithromycin for 28 days. Histopathological analyses of the lung tissues were performed under light microscopy.

**Results:** Normal histopathological changes were observed in the control group. Pulmonary fibrosis was significantly higher in the methotrexate group than in the other groups ( $p < 0.005$ ).

**Conclusions:** Clarithromycin was shown to be effective in protecting against methotrexate-induced pulmonary fibrosis; further studies should be performed to determine the dosage and safety.

**Key words:** clarithromycin, pulmonary fibrosis, rats.

## Introduction

Methotrexate (MTX) is a folic acid antagonist used as a cytotoxic agent in leukemia and several other cancer types and as an anti-inflammatory agent at lower doses in

## Streszczenie

**Wprowadzenie:** Metotreksat to środek cytotoksyczny stosowany w biacaczce oraz kilku innych typach raka, a także w mniejszych dawkach w chorobach autozapalnych, takich jak reumatoidalne zapalenie stawów, zeszywniające zapalenie stawów kręgosłupa czy łuszczycę. Antybiotyki makrolidowe są skuteczne przeciwko bakteriom Gram-dodatnim i Gram-ujemnym. Mają one również działanie przeciwzapalne. Kларыtromycyna jest makrolidem działającym przeciwzapalnie poprzez blokowanie kaskady sygnałowej p38 MAPK, która ma udział w toksyczności płucnej wywołanej metotreksatem.

**Cel:** Ocena skuteczności klarityromycyny w ochronie przed zwłóknieniem płuc na modelu szczura ze zwłóknieniem płuc wywołanym metotreksatem.

**Materiał i metody:** Grupę szczurów liczącą ogółem 30 samic podzielono na trzy grupy. Grupie I podawano sól fizjologiczną dootrzewnowo i dożołądkowo, grupie II – metotreksat doustnie w dawce 3 mg/kg m.c., a grupie III – metotreksat doustnie w dawce 3 mg/kg m.c. oraz klarityromycynę dootrzewnowo w dawce 200 mg/kg m.c. przez 28 dni. Tkanki płuc poddano następnie analizie histopatologicznej pod mikroskopem optycznym.

**Wyniki:** W grupie kontrolnej wykazano zwykłe zmiany histopatologiczne. Zwłóknienie płuc było istotnie większe w grupie otrzymującej sam metotreksat niż w pozostałych grupach ( $p < 0,005$ ).

**Wnioski:** Stwierdzono skuteczność klarityromycyny w ochronie przed zwłóknieniem płuc wywołanym metotreksatem. Należy jednak podjąć dalsze badania, aby określić dawkowanie leku i jego bezpieczeństwo.

**Słowa kluczowe:** klarityromycyna, zwłóknienie płuc, szczury.

auto-inflammatory diseases such as rheumatoid arthritis and psoriasis [1]. Some indirect side effects can be seen due to the cytotoxic nature of MTX. Hematopoietic suppression, hepatotoxicity, and lung toxicity are the most

**Address for correspondence:** Aydın Sarihan MD, Department of Emergency Medicine, Manisa State Hospital, Şehitler Mahallesi, Akhisar Cad. D:1, 45020 Manisa, Turkey, phone: +90 544 877 7117, e-mail: aydinsarihan@yahoo.com

**Received:** 27.05.2018, **accepted:** 29.09.2018.

important life-threatening side effects [2]. Long-term, low-dose MTX use is an important risk factor for lung toxicity. In addition, it may cause pulmonary toxicity in the case of high doses and intravenous use [3].

Hypersensitivity pneumonia [4], the direct toxic effect of MTX on lungs, and acquired infection are suggested mechanisms for the lung toxicity [5]. Experimental studies showed that MTX caused pulmonary toxicity, activating the p38 MAPK signal cascade [6]. The pulmonary damage developing with long-term, low-dose MTX use, particularly in rheumatologic diseases, is an important cause of morbidity and mortality [7]. Therefore, development of protective agents against adverse effects of MTX is of great importance.

Macrolide antibiotics are effective against gram-positive and Gram-negative bacteria [8]. They have anti-inflammatory activities as well [9]. Among the macrolide antibiotics, clarithromycin was shown to have particularly broad immunomodulatory activity [10]. In addition, clarithromycin is known to have anti-inflammatory activity by blocking the p38 MAPK signal cascade [11].

## Aim

Therefore, the current study aimed to investigate the possible role of clarithromycin in protecting against MTX-induced toxicity in the MTX-induced pulmonary fibrosis model.

## Material and methods

### Animals

The permission for animal studies was obtained from the Ethical Committee for Animal Studies at Suleyman Demirel University (21438139/2015/46), and the guidelines for the Care and Use of Laboratory animals were strictly followed. The study included 30 female, 10- to 12-week-old, 250 to 300 g rats, which were divided into three groups with 10 rats in each group. The rats were kept in an environmentally controlled room at constant temperature ( $21 \pm 1^\circ\text{C}$ ) and humidity ( $75 \pm 5\%$ ) under a 12 h light/dark cycle. The animals were acclimatized for 1 week before the

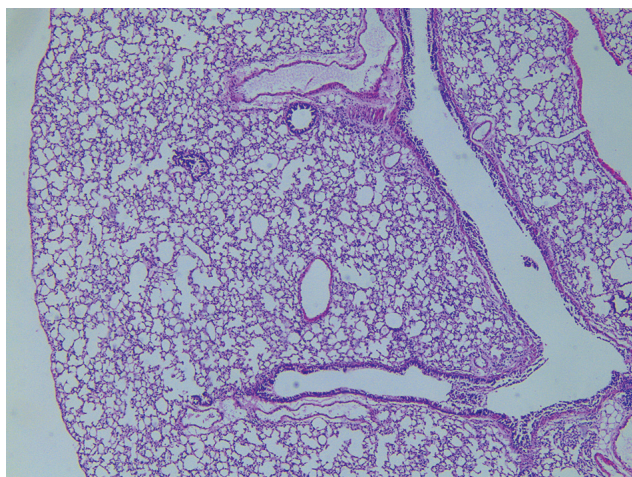


Fig. 1. Normal histological features

study and had free access to standard laboratory feed and water *ad libitum*. MTX and clarithromycin were purchased from Sigma-Aldrich Co. (St. Louis, MO, USA).

### Experimental protocol

Group I (control group) received an intragastric and intraperitoneal injection of saline. Group II (MTX group) received MTX orally 3 mg/kg for 28 days. Group III (MTX + clarithromycin group) received MTX orally 3 mg/kg and 200 mg/kg of intraperitoneally injected clarithromycin for 28 days. The doses and administration route of MTX and clarithromycin were based on previous studies and our preliminary experiments [12, 13]. The animals were euthanized after 28 days, and lung tissue samples were collected.

### Histopathological examination of lung tissues

Histopathological examination was performed in the Muğla Sıtkı Koçman University Department of Pathology. The lung samples were fixed in 10% neutral buffered formalin for 24 h, washed with tap water, and then serial dilutions of alcohol (methyl, ethyl, and absolute ethyl) were used for dehydration. Specimens were cleared in xylene and embedded in paraffin at  $56^\circ\text{C}$  in a hot air oven for 24 h. Paraffin beeswax tissue blocks were prepared for sectioning at 5  $\mu\text{m}$  thickness using a sledge microtome. Lung tissues were stained with hematoxylin and eosin (H + E) for histological examination. Tissue sections stained with H + E were examined by light microscopy for histopathological evaluation. The rats were photographed using an Olympus BX20 microscope (Tokyo, Japan).

### Statistical analysis

All statistical analyses were performed with SPSS v.15 (SPSS Inc., Chicago, IL). Median (minimum, maximum) values were presented to describe the histopathological grades. The relationships between study groups and histopathological grades were analyzed by the  $\chi^2$  test (Monte Carlo). A *p*-value of less than 0.05 was considered statistically significant.

## Results

In the examinations under the light microscope, lung tissues from the control group had normal histological features (Fig. 1). In group II (MTX group), grade 1 fibrosis was observed in 3 rats, grade 2 fibrosis in 3 rats, and grade 3 fibrosis in 1 rat. In group III (MTX + clarithromycin group), grade 1 fibrosis was found in 2 rats. The tissue damage in the MTX group (Figs. 2–4) was higher than in the control or MTX + clarithromycin groups (Tables I, II). A significant difference between the groups was found in multi-group comparisons of histopathological results ( $p = 0.001$ ). Post hoc pairwise comparisons of histopathological results showed that the control and MTX + clarithromycin groups were similar ( $p = 0.462$ ), the control and MTX groups were significantly different ( $p = 0.001$ ), and the MTX and



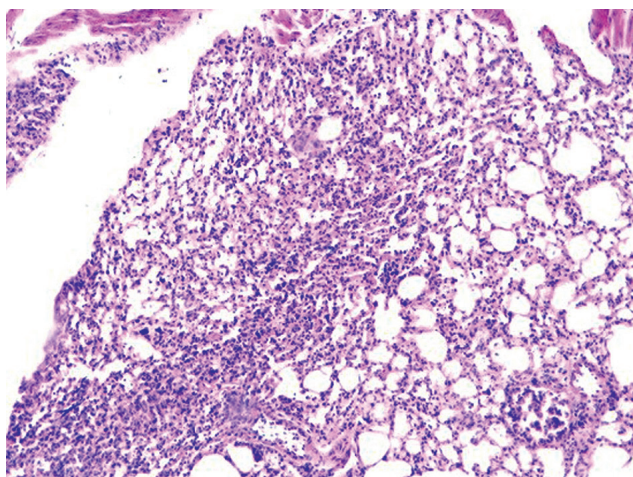


Fig. 2. Grade 1 fibrosis

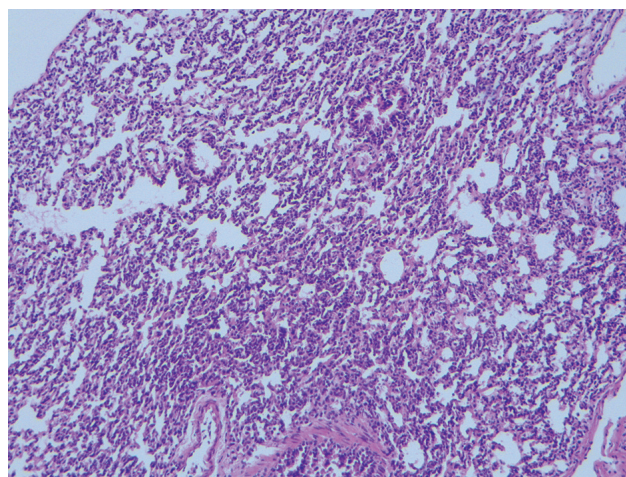


Fig. 3. Grade 2 fibrosis

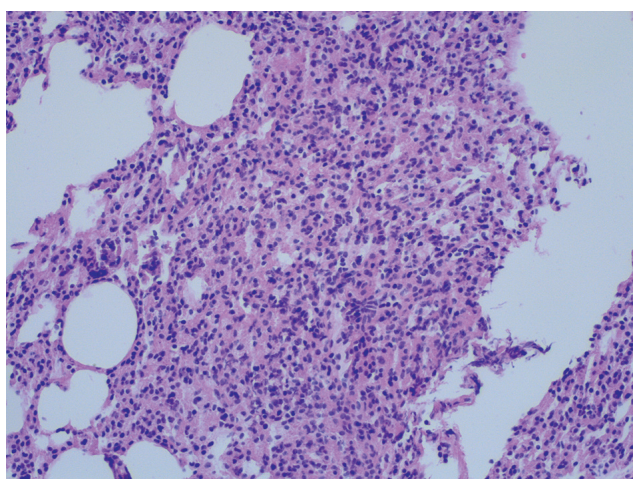


Fig. 4. Grade 3 fibrosis

MTX + clarithromycin groups were significantly different ( $p = 0.021$ ). The MTX group had higher histopathological grades than others, and the clarithromycin-treated group had lower lung-tissue damage.

## Discussion

In the current study, an experimental animal model was used to investigate the protective role of clarithromycin in MTX-induced pulmonary fibrosis. In the comparison between the MTX group and the MTX + clarithromycin group, development of pulmonary fibrosis was found reduced in the latter. To the best of our knowledge, the current study is the first experimental study to investigate the protective role of clarithromycin in MTX-induced pulmonary fibrosis. Some previous studies on lung fibrosis models were performed using the bleomycin and C57BL/6J strain mice [14]. Pulmonary fibrosis models using rats were also successfully created [15]. The number of MTX-induced pulmonary fibrosis models in the literature is limited [12]. In the current study, it was observed that the pulmonary fibrosis developed successfully using MTX in rats.

The MTX-induced side effects such as gastritis and myelosuppression were shown to decrease with the use of

Table I. Median fibrosis scores

Grade	Control		MTX		MTX + CRM		P-value
	n	%	n	%	n	%	
0	7	100.00	0	0.00	5	71.43	0.001
1	0	0.00	3	42.86	2	28.57	
2	0	0.00	3	42.86	0	0.00	
3	0	0.00	1	14.29	0	0.00	
Total	7	100.00	7	100.00	7	100.00	

Table II. Median histopathological grades

Group	Grade	
	Median	Min.–max.
Control	0	0–0
MTX	2	1–3
MTX + CRM	0	0–1

follic and folic acid together with MTX, but these did not have any effect on the pulmonary toxicity [16]. Although minocycline, an agent to reduce the MTX-induced pulmonary toxicity, was found effective in the MTX-induced pulmonary fibrosis model, it has very limited use since it is expensive [17].

Methotrexate is suggested to cause pulmonary damage by increasing the TNF- $\alpha$ , IL-1, IL-8, and MCP-1 release through the p38 MAPK signal cascade (TAK1→MKK3/MKK6→p38 MAPK→MAPKAPK2→HSP27) [18]. In addition, it was also suggested that MTX might lead to pulmonary damage by increasing the reactive oxygen products [19]. Macrolide antibiotics have antimicrobial as well as anti-inflammatory activities. The latter was considered to occur through reducing the pro-inflammatory mediator release [20]. Clarithromycin, in particular, was shown to have anti-inflammatory activity by blocking the p38 MAPK signal cascade [11], and thus was considered to have a protective effect against MTX-induced pulmonary fibrosis.

François *et al.* showed that the B-cell activating factor (BAFF) could play a key role in the development of fibrosis,

particularly by increasing the IL-17 release from T lymphocytes [21]. Clarithromycin is known to show anti-inflammatory activity by decreasing the IL-17 release in chronic inflammatory diseases [10, 22]. In the current study, it was supposed that clarithromycin could show antifibrotic activity through this mechanism.

In the current study, a protective effect of clarithromycin against MTX-induced pulmonary fibrosis was observed; however, the small sample size, the lack of an examination for the oxidants and antioxidants in tissue and serum, and the lack of electron microscopic examination of the tissues were the limitations of the study. In conclusion, clarithromycin may have a protective effect against MTX-induced pulmonary fibrosis but further studies should be performed to determine the dosage and safety.

### Acknowledgments

We are grateful to Muğla Sıtkı Koçman University Hospital and School of Medicine for facility access.

### Disclosure

The authors report no conflict of interest.

### References

- Dalaklioglu S, Genc GE, Aksoy NH, Akcıt F, Gumuslu S. Resveratrol ameliorates methotrexate-induced hepatotoxicity in rats via inhibition of lipid peroxidation. *Hum Exp Toxicol* 2013; 32: 662-671.
- Cetin A, Kaynar L, Eser B, Karada C, Saraymen B, Öztürk A. Beneficial effects of propolis on methotrexate-induced liver injury in rats. *Acta Oncologica Turcica* 2011; 44: 18-23.
- Imokawa S, Colby TV, Leslie KO, Helmers RA. Methotrexate pneumonitis: review of the literature and histopathological findings in nine patients. *Eur Respir J* 2000; 15: 373-381.
- Lynch JP 3<sup>rd</sup>, McCune WJ. Immunosuppressive and cytotoxic pharmacotherapy for pulmonary disorders. *Am J Respir Crit Care Med* 1997; 155: 395-420.
- Kim YJ, Song M, Ryu JC. Mechanisms underlying methotrexate-induced pulmonary toxicity. *Expert Opin Drug Saf* 2009; 8: 451-458.
- Kim YJ, Song M, Ryu JC. Inflammation in methotrexate-induced pulmonary toxicity occurs via the p38 MAPK pathway. *Toxicology* 2009; 256: 183-190.
- Świerkot J, Szechiński J. Methotrexate in rheumatoid arthritis. *Pharmacol Rep* 2006; 58: 473-492.
- Asano K, Suzuki M, Shimane T, Suzaki H. Suppressive activity of co-stimulatory molecule expressions on splenic B lymphocytes by a macrolide antibiotic, roxithromycin in vitro. *Int Immunopharm* 2001; 1: 1385-1392.
- Culic O, Erakovic V, Parnham MJ. Anti-inflammatory effects of macrolide antibiotics. *Eur J Pharmacol* 2001; 429: 209-229.
- Essilfie AT, Horvat JC, Kim RY, Mayall JR, Pinkerton JW, Beckett EL, Starkey MR, Simpson JL, Foster PS, Gibson PG, Hansbro PM. Macrolide therapy suppresses key features of experimental steroid-sensitive and steroid-insensitive asthma. *Thorax* 2015; 70: 458-467.
- Furuya A, Asano K, Shoji N, Hirano K, Hamasaki T, Suzaki H. Suppression of nitric oxide production from nasal fibroblasts by metabolized clarithromycin in vitro. *J Inflamm* 2010; 7: 56-77.
- Ohbayashi M, Suzuki M, Yashiro Y, Fukuwaka S, Yasuda M, Kohyama N, Kobayashi Y, Yamamoto T. Induction of pulmonary fibrosis by methotrexate treatment in mice lung in vivo and in vitro. *J Toxicol Sci* 2010; 35: 353-661.
- Hrvacic B, Bosnjak B, Bosnar M, Ferencic Z, Glojnaric I, Erakovic Haber V. Clarithromycin suppresses airway hyperresponsiveness and inflammation in mouse models of asthma. *Eur J Pharmacol* 2009; 616: 236-243.
- Harrison JH Jr, Lazo JS. High dose continuous infusion of bleomycin in mice: a new model for drug-induced pulmonary fibrosis. *J Pharmacol Exp Ther* 1987; 243: 1185-1194.
- Javadi I, Emami S. The antioxidative effect of chamomile, anthocyanoside and their combination on bleomycin-induced pulmonary fibrosis in rat. *Med Arch* 2015; 69: 229-231.
- Dijkmans BA. Folate supplementation and methotrexate. *Br J Rheumatol* 1995; 34: 1172-1174.
- Kalemci S, Dirican N, Cetin ES, Sozen H, Uner AG, Yaylali A, Aksun S, Karacam V, Ulger E, Sutcu R, Dirican A. The efficacy of minocycline against methotrexate-induced pulmonary fibrosis in mice. *Eur Rev Med Pharmacol Sci* 2013; 17: 3334-3340.
- Turesson C, Matteson EL. Genetics of rheumatoid arthritis. *Mayo Clin Proc* 2006; 81: 94-101.
- Hemeida RA, Mohafez OM. Curcumin attenuates methotrexate-induced hepatic oxidative damage in mice. *J Egypt Natl Canc Inst* 2008; 20: 141-148.
- Friedlander AL, Albert RK. Chronic macrolide therapy in inflammatory airways diseases. *Chest* 2010; 138: 1202-1212.
- François A, Gombault A, Villeret B, Alsaleh G, Fanny M, Gasse P, Adam SM, Crestani B, Sibilia J, Schneider P, Bahram S, Quesniaux V, Ryffel B, Wachsmann D, Gottenberg JE, Couillin I. B cell activating factor is central to bleomycin- and IL-17-mediated experimental pulmonary fibrosis. *J Autoimmun* 2015; 56: 1-11.
- Fouka E, Lampridou E, Arvanitidis K, Filidou E, Kolios G, Miltiades P, Paraskakis E, Antoniadis A, Kotsianidis I, Bouros D. Low-dose clarithromycin therapy modulates Th17 response in non-cystic fibrosis bronchiectasis patients. *Lung* 2014; 192: 849-855.